

AMELIORATIVE EFFECT OF VITAMINS A, E, D & C ON AMPLIGO A SYNTHETIC INSECTICIDE INDUCING TOXICITY ON RABBIT ADRENAL GLAND

Settar A.^{1*}, Khaldoun Oularbi H.², Tarzaali D.³, Mekhaldi F.⁴

¹ Laboratory of Biotechnology, Environment and Health, Department of Food Sciences, Faculty of Nature and Life Sciences Blida 1 University, BP 270. Soumaa. Blida. Algeria

² Faculty of Nature and Life Sciences Blida 1 University , BP 270. Soumaa. Blida. Algeria

³ Institute of Veterinary Sciences Blida 1 University , BP270.Soumaa.Blida.Algeria

⁴ Department of natural sciences, ENS Kouba, BP 92, Vieux Kouba Alger, Algeria

*Corresponding author: settamina95@gmail.com

ABSTRACT

In order to evaluate the toxic effect of Ampligo® 150 ZC on the rabbit adrenal gland and the probable ameliorative effect of vitamins A, E, D and C association. Fifteen male rabbits "*oryctolagus cuniculus*" were divided into three groups: control; Ampligo (AP) and Ampligo+ vitamins (AP+VIT). The toxic effect of Ampligo was measured on body and adrenal weights, cortisol plasma level and adrenal tissues. Results shows an increase in body weight gain in all groups and the higher body weight gain was noticed in the AP group. A notable increase in adrenal weight in AP treated group was observed, and cortisol plasma level was significantly increased in AP+VIT group. The histological study revealed a disorganization of the adrenal tissues in rabbits treated with Ampligo and a notable amelioration of the adrenal parenchyma was observed in the AP+VIT treated rabbits. The present results indicate that Ampligo® 150 ZC cause various alterations in adrenal male rabbits and supplementation with a combination of vitamins A,E,D and C induce beneficial effect in reducing the insecticide toxicity.

Key words: Ampligo , Rabbits , Vitamins , Adrenal gland, Histopathology.

INTRODUCTION

As a result of technological development, agricultural productivity continues to improve due to the green revolution strategy. This improvement requires the massive use of pesticides for pest management. Indeed, pesticides play an important role in increasing food production and provide a safe and secure food supply for human and pets. However, pesticides can cause a serious hazard as they are non-biodegradable. Their presence in the environment leads to an incidence of toxicological risks in mammals (Ecobichon, 2000). Insecticides are the most widely used pesticides, and are known to disrupt the endocrine system and generate oxidative stress (McKinlay *et al.*, 2008; Abdollahi *et al.*, 2004). Ampligo® 150 ZC (chlorantraniliprole 9.3% + lambda cyhalothrin 4.6%) (AP) is a new insecticide formulated from a combination of anthranilic diamide and synthetic type II pyrethroid used against wide range of insect pests. In fact, it has been shown that lambda cyhalothrin generates oxidative stress (Yousef, 2010 ; El-Demerdash, 2007). In the other hand, the toxic effect of chlorantraniliprole seems to be unknown. To address this issue, supplementation with antioxidants could be very beneficial. Vitamin A is a fat-soluble micronutrient which can be found in several varieties and play crucial role in many biological functions including immunity (Polcz and Barbul, 2019). Vitamin D is a hydrophobic vitamin and acts as steroid hormone and have an antioxidant proprieties (Uberti *et al.*, 2014). α tocopherol (vitamin E) is a lipophilic chain-breaking antioxidant and a well-known protector from oxidative damages. Vitamin C (ascorbic acid) is a hydrophilic antioxidant able to control the oxidative stress and environmental toxicities (Guo *et al.*, 2016). In our knowledge, there was no previous study showing the beneficial effect of this vitamins association in reducing the Ampligo's damages in the adrenal gland. The objective of this study is to evaluate the toxicity of a synthetic insecticide Ampligo® 150 ZC on the male rabbit adrenal gland and to demonstrate the probable ameliorative effect of vitamins A, D, E & C association.

MATERIALS AND METHODS

Animals and experimental design

A total of 15 male rabbits "*oryctolagus cuniculus*" aging 4 months and weighing 2,5 - 3kg were obtained from the Technical breeding institute (ITLVE Baba Ali) and moved to Saad Dahleb Blida 1 university for the experimentation. The animals were housed in metal cages, under controlled room temperature ($22 \pm 2^\circ\text{C}$), humidity (45–65%), and artificial lighting (12 h/12 h light/dark cycle) and received standard diet and water *ad libitum*. Throughout the experimentation, rabbits were daily weighed using an electronic scale. The acclimatization of the animals lasted for 3 weeks. Rabbits were randomly divided into 3 groups (n=5) : the first group served as control and received distilled water; the AP group which received a dose of 20 mg/kg/bw Ampligo insecticide, and the last group was the AP+VIT which received a dose of 20 mg/kg/bw Ampligo and 0.5 ml of VIT AD3E INJ. + 200mg/kg of vitamin C in alternation. The experimentation period lasted for 28 days.

Chemical Analysis

After 28 days of treatment blood samples were taken at 9 am and moved to centrifugation at 3.000 rpm for 20 minutes. Plasma cortisol levels were measured by immunoassay technique using commercial assay kits (VITROS 1074053). Rabbits were scarified by decapitation and adrenal glands were weighed, fixed in 10% buffered formalin, embedded in paraffin and stained with hematoxylin and eosin (HE) for the histopathological examination, then digital images of adrenal parenchyma were obtained by photomicroscope.

Statistical Analysis

Data were statistically analyzed using Statistica version 10.0 (stat soft Inc., Tulsa, Oklahoma, USA) and values were presented as mean \pm SEM using one-way analysis of variance followed by the Duncan's post hoc tests. $p < 0.05$ was considered statistically significant.

RESULTS AND DISCUSSION

Effect of the chemical administration on the rabbits' body and the adrenal gland weights:

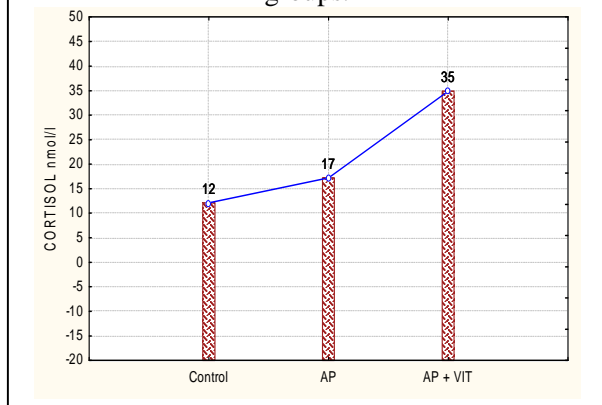
Table 1: Body weight gain throughout 4 weeks of treatment, absolute adrenals weight in rabbits from control and AP and AP+VIT. * $p < 0.05$

Parameter/group	Control n=5	AP n=5	AP+VIT n=5
Body weight (kg)			
Acclimatization	2,22 \pm 27,62	2,48 \pm 29,56	2,53 \pm 52,09
Treatment: week 1	2,460 \pm 25,23	2,721 \pm 29,26	2,51 \pm 55,40
Treatment : week 2	2,668 \pm 22,40	2,943 \pm 35,03	2,55 \pm 64,49
Treatment : week 3	2,830 \pm 25,40	3,051 \pm 43,20	2,62 \pm 73,52
Treatment : week 4	2,948 \pm 28,83	3,17 \pm 42,62*	2,69 \pm 85,43
Adrenals weight (g)	0,300 \pm 0,005	0,557 \pm 0,083*	0,432 \pm 0,042

A continuous increase in rabbits body weight was observed throughout the experimentation, and the higher body weight was noticed in the AP group. These results indicate that the Ampligo insecticide promotes weight gain. Otherwise, it has been demonstrated that lambda cyhalothrin reduce rabbits body weight (Yousef, 2010). In this context, this increase is due to chlorantraniliprole molecule. Significant increase in the adrenals weight appeared as a result of fat deposit in adrenal tissues and reflect a physiological stress in rabbit body, also it has been shown that pyrethroid family increase the adrenal weight (Liu *et al.*, 2006 ; Sangha *et al.*, 2011).

Effect of the chemical administration on the rabbits' cortisol plasma level:

Figure 1: Effect of treatment on the cortisol plasma level after 28 days in the three rabbit groups.



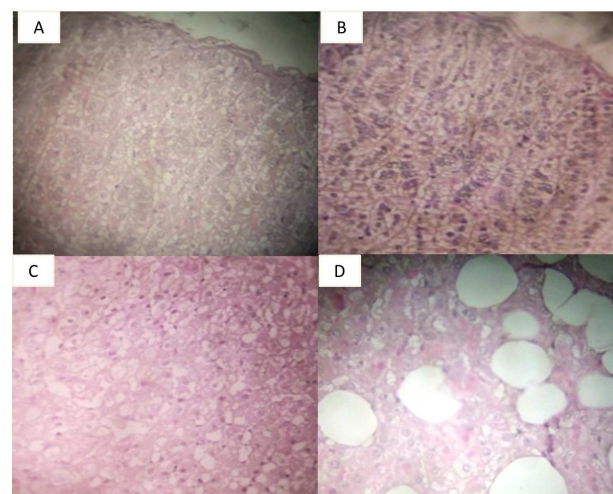
A significant increase ($p < 0,05$) in cortisol plasma level was observed in AP+ VIT group, also we noticed an increase in AP group. It has been found that pesticides especially insecticides alter the normal functioning of the endocrine system (Mnif *et al.*, 2011). Known as anti-inflammatory hormone, cortisol mobilizes the organism to fight stress, its elevated levels in AP and AP+VIT treated groups indicates that rabbits are in stress condition. The non-significant increase of cortisol level in the group treated with Ampligo may be due to the toxic effect of the insecticide on adrenal tissues and affect its physiological function. However, the vitamins' supplementation appears as a protection tool of the adrenal functioning, thus it helps to cortisol releasing.

Effect of the chemical administration on the rabbits' adrenal tissues:

The histological study of the adrenal parenchyma showed a normal architecture of the cortex and adrenal medulla in the control group. The three zones of the cortex were clearly distinct this reflects the normal organ weight and cortisol blood level. In Ampligo treated rabbits a disorganization of the adrenal tissues was observed with pyknotic nuclei and numerous vacuoles. Supplementation with vitamins A, E, D and C in the third group showed a clear difference compared to the AP group, we noticed a similar organization of the adrenal parenchyma to control group.

The vacuolization in adrenal tissues of rabbits treated with Ampligo explain the increase of the body weight and the adrenal hypertrophy. Otherwise, the addition of vitamins improves clearly the alteration induced by Ampligo insecticide. The histotoxicity of lambda cyhalothrin in the adrenal gland was demonstrated in the study of (Khaloudoun Oularbi, 2014). We can also say that chlorantraniliprole accentuates this toxicity. In the other hand, ameliorative effect of vitamins with antioxidant action like vitamin C and E against lambda cyhalothrin and other pesticides has been object of several studies (Fetoui, 2008,2009; Yousef, 2010). The association of vitamins A,E,D and C against Ampligo's toxicity is the first in the field.

Figure 2: Histology of adrenal gland (A and B) the histoarchitecture is similar in control and AP+VIT rabbits GRx20, (C and D) rabbits treated with AP shows a disorganization of the adrenal parenchyma and vacuoles deposit GRx 20;40 (HE stain).



CONCLUSIONS

This study demonstrates that vitamins A, E, D and C combination has a potential ameliorative effect against the subacute exposure to Ampligo 150 ZC in adrenal gland of male rabbit. Pesticides predispose mammals to several physiological alterations, thus a need to improve the use of vitamins to prevent/minimize its damages.

REFERENCES

- Abdollahi, Mohammad, Akram Ranjbar, Shahin Shadnia, Shekoufeh Nikfar, and Ali Rezaiee. 2004. "Pesticides and Oxidative Stress: A Review." *Medical Science Monitor* 10 (6): RA141–147.
- Ecobichon, Donald J. 2000. "Our Changing Perspectives on Benefits and Risks of Pesticides: A Historical Overview." *Neurotoxicology* 21 (1–2): 211–218.
- El-Demerdash, Fatma M. 2007. "Lambda-Cyhalothrin-Induced Changes in Oxidative Stress Biomarkers in Rabbit Erythrocytes and Alleviation Effect of Some Antioxidants." *Toxicology in Vitro* 21 (3): 392–397.
- Fetoui, Hamadi, El Mouldi Garoui, Fatma Makni-ayadi, and Najiba Zeghal. 2008. "Oxidative Stress Induced by Lambda-Cyhalothrin (LTC) in Rat Erythrocytes and Brain: Attenuation by Vitamin C." *Environmental Toxicology and Pharmacology* 26(2): 225–231.
- Fetoui, Hamadi, El Mouldi Garoui, and Najiba Zeghal. 2009. "Lambda-Cyhalothrin-Induced Biochemical and Histopathological Changes in the Liver of Rats: Ameliorative Effect of Ascorbic Acid." *Experimental and Toxicologic Pathology* 61 (3): 189–196.
- Guo, Meng, Jin-Hong Liu, Xiao Ma, De-Xu Luo, Zhen-Hui Gong, and Ming-Hui Lu. 2016. "The Plant Heat Stress Transcription Factors (HSFs): Structure, Regulation, and Function in Response to Abiotic Stresses." *Frontiers in Plant Science* 7: 114.
- Khaldoun Oularbi, Hassina. 2014. "Biochemical and Histopathological Changes in the Kidney and Adrenal Gland of Rats Following Repeated Exposure to Lambda-Cyhalothrin." *Journal of Xenobiotics* 4 (1).
- Liu, Ping, Xiaoxiao Song, Weihong Yuan, Weihua Wen, Xinan Wu, Jian Li, and Xuemin Chen. 2006. "Effects of Cypermethrin and Methyl Parathion Mixtures on Hormone Levels and Immune Functions in Wistar Rats." *Archives of Toxicology* 80 (7): 449–457.
- McKinlay, R., J. A. Plant, J. N. B. Bell, and N. Voulvoulis. 2008. "Endocrine Disrupting Pesticides: Implications for Risk Assessment." *Environment International* 34 (2): 168–183.
- Mnif, Wissem, Aziza Ibn Hadj Hassine, Aicha Bouaziz, Aghleb Bartegi, Olivier Thomas, and Benoit Roig. 2011. "Effect of Endocrine Disruptor Pesticides: A Review." *International Journal of Environmental Research and Public Health* 8 (6):2265–2303.
- Polcz, Monica E., and Adrian Barbul. 2019. "The Role of Vitamin A in Wound Healing." *Nutrition in Clinical Practice* 34 (5): 695–700.
- Sangha, G. K., Kamalpreet Kaur, K. S. Khera, and Balwinder Singh. 2011. "Toxicological Effects of Cypermethrin on Female Albino Rats." *Toxicology International* 18 (1): 5.
- Uberti, F., D. Lattuada, V. Morsanuto, U. Nava, G. Bolis, G. Vacca, D. F. Squarzanti, C. Cisari, and C. Molinari. 2014. "Vitamin D Protects Human Endothelial Cells from Oxidative Stress through the Autophagic and Survival Pathways." *The Journal of Clinical Endocrinology & Metabolism* 99 (4): 1367–174.
- Yousef, Mokhtar I. 2010. "Vitamin E Modulates Reproductive Toxicity of Pyrethroid Lambda-Cyhalothrin in Male Rabbits." *Food and Chemical Toxicology* 48 (5): 1152–1159.