

AMPLIGO® INSECTICIDE INDUCES INJURIES ON THE TESTES OF RABBIT *ORYCTOLAGUS CUNICULUS*: ALLEVIATING EFFECTS OF VITAMINS C AND E (ASCORBATE/ α -TOCOPHEROL)

Khaldoun Oularbi H^{1,2*}, Makhlof C^{1,2}, Bokreta S^{1,2}, Settar A¹, Tarzali D¹, Zitouni G³, Hamadou D², Kais S², Daoudi-Zerrouki N.²

¹Department of Biology, Faculty of Nature and Life Sciences, University Blida 1, BP 270. Soumaa. Blida. Algeria

²Natural Resources Laboratory, University Mouloud Mammeri, BP 15017. Tizi-Ouzou. Algeria

³Technical Breeding Institute (Institut Technique d'Élevage (ITELV), 16111 Baba Ali, Alger, Algeria

* Correspondance Khaldoun Oularbi Hassina : e-mail : khaldounhassina@hotmail.fr

ABSTRACT

This study was conducted to evaluate the potential reproductive toxicity induced by “Ampligo® 150 ZC” (AP) (Chlorantraniliprole 9.3% + Lambda cyhalothrin 4.6% ZC) in male rabbits and to examine the protective effect of vitamins C and E (CE) against AP hormonal and histological toxicity. Twenty male rabbits “*Oryctolagus cuniculus*” were divided into four groups: Control, vitamins C and E (CE), ampligo (AP) and AP plus CE (AP+CE) groups. Testosterone, follicle-stimulating hormone (FSH), and luteinizing hormone (LH) were measured from the serum, while the testes tissue samples were used for histopathological examinations. Ampligo exposition induced decreased body weight gain and reproductive organs testes and epididymis weights. This study revealed no changes in serum hormonal LH and FSH concentrations, while, testosterone concentration were found significantly reduced in AP treated group than the other groups. Our observations also showed that treatment with AP significantly decreased the morphometrical parameters of seminiferous tubules. Histomorphometrical examination revealed a decrease in germinal layer thickness, disorganization of seminiferous tubules, degeneration of the epithelium and congestion. Vitamins C and E supplementation with AP significantly reversed the above mentioned damages. The present results indicate that vitamins C and E combination exerts curative effects against Ampligo®-induced male reproductive toxicity.

Key words: Ampligo 150ZC. Vitamins C and E, Hormonal Parameters, Testicle Histology, Rabbits

INTRODUCTION

The causal factors of male infertility consist of internal and external factors able to disrupt the spermatogenesis; principally exposure to environmental chemicals such as pesticides (insecticides) (Fang *et al.*, 2013), heavy metals (Yamaguchia *et al.* 2009), high temperature, smoking, stress, alcohol and obesity (Shrem *et al.*, 2019). Synthetic pyrethroids have been considered potentially toxic to male reproductive system (Kilian *et al.*, 2007), they have ability to disrupt estrogen signaling and affect male reproductive organs and semen quality. Exposure to pyrethroids causes decreased sperm counts, impairment of sperm motility, reduced fertilization ability, producing abnormal sperm in the rodents following repeated exposure (Wang *et al.*, 2010). Ampligo® 150 ZC” (AP) is a new insecticide formulation containing chlorantraniliprole 9.3% and lambda cyhalothrin 4.6%. Chlorantraniliprole is an anthranilic diamide insecticide while lambda cyhalothrin (LCT) is a type II pyrethroid insecticide widely used in pest management. During pyrethroid metabolism, reactive oxygen species (ROS) were generated and caused oxidative stress in intoxicated animals (Yousef *et al.*, 2006). Antioxidants can protect against the damaging effect of oxygen species on male infertility. Numerous vitamins have proven beneficial in treating male reproduction, such as vitamin C (khaldoun oularbi *et al.*, 2014; khaldoun oularbi *et al.*, 2017), vitamin E, folic acid (Yousef *et al.*, 2006) vitamin E (Mohamed *et al.*, 2014). Ascorbic acid is a water-soluble antioxidant which has potential protective effects on oxidative stress and environmental toxicities (Guo *et al.*, 2016). Vitamin E is a potent lipid soluble antioxidant in biological systems that play important roles in animal health by inactivating harmful free radicals

produced through normal cellular activity and from various stressors (Yousef *et al.*, 2010). The main aim of this study was (1) to assess the toxic effect of a new insecticide formulation Ampligo® on rabbit's testicle histology and endocrine testicular functions and (2) to investigate the Protective effect of vitamins C and E combination against ampligo® reproductive toxicity in male rabbit .

MATERIALS AND METHODS

Animals and experimental design

Twenty male adults rabbits "*oryctolagus cuniculus*" (2.5 – 2.9 Kg) were obtained from the Technical Breeding Institute (ITELV, Baba-Ali) and kept for experimentation in the CRD Saïdal Algeria. The rabbits were acclimated for a period of 3 weeks and had free access to food and water *ad libitum*. Animals were randomly distributed into four groups : (1) control group; (2) CE group, rabbits were given Vit E 200 mg/kg + Vitamin C 200 mg/kg; (3) Ampligo® group (AP), rabbits were administered ampligo (at dose that containing 12.24 mg/kg per day LCT and 24.48 mg/kg per day); (4) in group AP+CE, rabbits were given the same doses of vitamins C and E as in group CE 12h after the administration of ampligo treatment of rabbits.

Chemical Analyses

On the day 21 after treatment, rabbits were sacrificed by decapitation and blood samples were collected. Plasma was obtained by centrifugating 5 mL of blood per rabbit at 2.000 rpm for 15 minutes. Samples were then frozen and stored at -20 degrees Celsius until processing. Plasma concentrations measured included: LH (ref: 11775863122), FSH (ref: 11732234122) and testosterone (ref: 05200067190), by electrochemiluminescence immunoassay (ECLIA). This assay is based on the principle of competitive union using a monoclonal antibody with reagents for the Cobas e-411 immunology analyzer (Roche). The whole testes and epididymis were weighed than testes were dissected out, collected, fixed in 10% neutral buffered formaldehyde solution for histological examination, processed, sectioned (2-3µm) and stained with hematoxylin and eosin (HE). For morphometrical analysis, digital images of testicular parenchyma were obtained by photomicroscope in order to determine the diameter of the area of seminiferous tubules, the epithelium height and the luminal diameter of the seminiferous tubule using the Axio Vision Ziess image analysis software.

Statistical Analysis

All statistical analyses were performed using Statistica version 10.0 (Stat Soft Inc., Tulsa, Oklahoma, USA). Data were calculated using one-way analysis of variance followed by the Duncan's post hoc tests. Data were expressed as the mean ± SD. A p-value < 0.05 was considered as the level of significance.

RESULTS AND DISCUSSION

Table 1: Body weight gain (% BWG), average feed and water intake in rabbits from control, CE, AP and AP+CE-treated groups, 21 days after treatment.

Groups / Period	CONTROL	CE	AP	AP+CE
Initial BW (Kg)	2.70 ± 0.02	2.65 ± 0.03	2.61 ± 0.06	2.83 ± 0.02
Final BW (Kg)	3.04 ± 0.02	2.99 ± 0.28	2.81 ± 0.05*	3.16 ± 0.34
% BWG	3,38	3,45	1,99*	3,29
Absolute : Testis + epididymis Weight (g)	5.32 ± 0.03	4.99 ± 0.41	4.32 ± 0.16*	6.1 ± 0.2
Relative : Testis + epididymis Weight	0.18 ± 0.01	0.17 ± 0.02	0.13 ± 0.01*	0.19 ± 0.02
Average feed intake (g / rabbit)				
Acclimatation	98.2 ± 5.1	97.4 ± 7.7	86.3 ± 4.0	98.7 ± 6.3
Experimentation	164.0 ± 4.6	185.5 ± 10.1	159.9 ± 13.0*	176.4 ± 6.5
Average water consumption (ml / rabbit)				
Acclimatation	31.2 ± 0.7	30.8 ± 2.6	31.6 ± 1.5	34.3 ± 1.6
Experimentation	138.2 ± 5.1	117.2 ± 6.9	100.08±8.08*	106.8±7.33

Results are given as a mean ± SD for five rabbits in each group. * p < 0.05.

Effects of treatments on food intake, water consumption, body and Testes and epididymis weights:

In ampligo-treated rabbits, feed intake and water consumption were reduced when compared with controls. The decrease in the body weight of treated rabbits with ampligo appeared as a result of lesser intake of feed. Significant

Table 1: Body weight gain (% BWG), average feed and water intake in rabbits from control, CE, AP and AP+CE-treated groups, 21 days after treatment.

Groups / Period	CONTROL	CE	AP	AP+CE
Initial BW (Kg)	2.70 ± 0.02	2.65 ± 0.03	2.61 ± 0.06	2.83 ± 0.02
Final BW (Kg)	3.04 ± 0.02	2.99 ± 0.28	2.81 ± 0.05*	3.16 ± 0.34
% BWG	3,38	3,45	1,99*	3,29
Absolute : Testis + epididymis Weight (g)	5.32 ± 0.03	4.99 ± 0.41	4.32 ± 0.16*	6.1 ± 0.2
Relative : Testis + epididymis Weight	0.18 ± 0.01	0.17 ± 0.02	0.13 ± 0.01*	0.19 ± 0.02
Average feed intake (g / rabbit)				
Acclimatation	98.2 ± 5.1	97.4 ± 7.7	86.3 ± 4.0	98.7 ± 6.3
Experimentation	164.0 ± 4.6	185.5 ± 10.1	159.9 ± 13.0*	176.4 ± 6.5
Average water consumption (ml / rabbit)				
Acclimatation	31.2 ± 0.7	30.8 ± 2.6	31.6 ± 1.5	34.3 ± 1.6
Experimentation	138.2 ± 5.1	117.2 ± 6.9	100.08 ± 8.08*	106.8 ± 7.33

Results are given as a mean ± SD for five rabbits in each group. * p < 0.05.
CE: vitamins C and E group **AP:** Ampligo group; **AP+CE:** ampligo + vitamins C and E - treated groups.

differences in testis plus epididymis weights were observed in ampligo treated group. Those results corroborated with the findings of previous studies (Yousef *et al.*, 2010; Khaldoun Oularbi *et al.*, 2014) showing that exposure to pyrethroids causes decreased body and organs weights in the rodents following repeated exposure.

Effects of treatments on plasma hormonal parameters and morphometrical

parameters

The synthetic pyrethroids are expected to cause deleterious effects on most of the organs and especially on the male reproductive system. Lambda-cyhalothrin caused sexual dysfunction in male rats and caused alterations in reproduction (Yousef *et al.*, 2010; Ratnasooriya *et al.*, 2002). The effects of ampligo® treatment on testosterone, FSH and LH in plasma were analyzed. This study revealed no changes in the hormone plasma levels of LH and FSH. The concentrations of testosterone in plasma reduced significantly in the AP group. Similarly to Yousef *et al.* (2010) treatment with lambda cyhalothrin insecticide decreased testosterone levels. Li *et al.* (2013) established that decrease in serum levels of testosterone in the adult rats exposed to cypermethrin could result from decreases in the number of Leydig cells and/or the damage of their structure. Morphometric study demonstrated a decrease in the total area, diameter of the epithelium of seminiferous tubules of AP rabbits. Vitamins C E supplementation with AP significantly reversed the above mentioned damages.

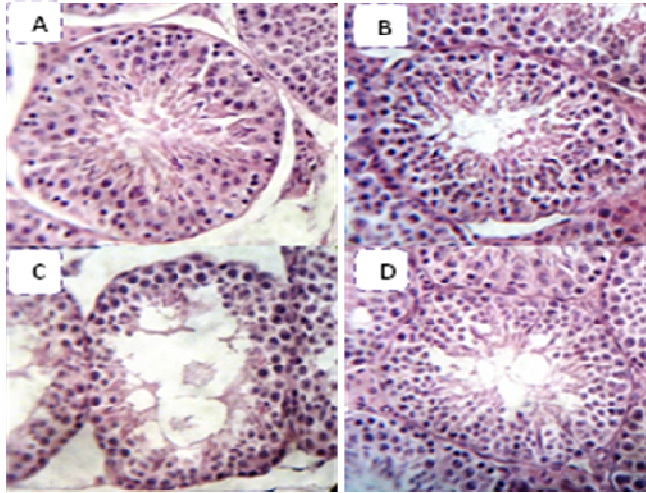
Table 2: Hormone concentrations in rabbit's control and treated-groups (CE, AP, AP+CE) and histomorphometric parameters of seminiferous tubules at the end of the experimental period. EH: Epithelium height, LD: Luminal diameter

Groups	Control	CE	AP	AP + CE
(1) Hormonal Parameters				
FSH (ng/ml)	0.33± 0.00	0.35±0.01	0.31±0.00	0.29±0.86
LH (ng/ml)	0.21+0.01	0.23+0.03	0.24+0.07	0.21+0.00
Testosterone (ng/ml)	2.91+0.8	13.36+0.23	1.84+ 0.25**	5.66+5.42*
(2) Histomorphometric Parameters of seminiferous tubules				
Total area (µm²)	79.85.x10 ³ ±15.2x10 ²	63.9x10 ³ ±17.4 x10 ²	45.91x10 ³ ± 16.5 x10 ² *	52.73 x10 ³ ± 21.1 x10 ²
EH (µm)	77.5 ± 12.4	79.0 ± 11.2	49.2 ± 7.91*	51.4 ± 6.93
LD (µm)	112..9 ± 24.4	101..8 ± 19.3	99..0 ± 18.7	95..6 ± 17.5
EH / LD	0.68 ± 0.2	0.77 ± 0.1	0.49 ± 0.1*	0.53 ± 0.1
LD/ EH	1.45 ± 0.3	1.28 ± 0.2	2.01 ± 0.4*	1.85 ± 0.4

Results are given as a mean \pm SD for five rabbits in each group. * $p < 0.05$.

CE: vitamins C and E group AP: Ampligo group; AP+CE: ampligo + vitamins C and E -treated groups.

Figure 1: Histology of Testis: (A and B) the histoarchitecture of the testis is intact in control and CE rabbits. (C) Rabbits treated with AP show disorganization of seminiferous tubules and degeneration of the epithelium and congestion. C and D) Rabbits treated AP+ CE (Haematoxylin Eosin stain, X 400).

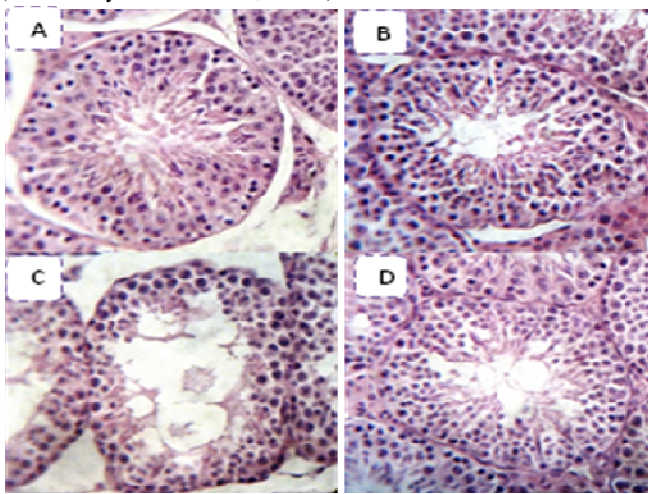


Effect of treatments on testis histological structure

The testis section of control and CE-treated rabbits appeared normal. It is formed of many somniferous tubules with a normal spermatogenic lineage. The testicular parenchyma showed structural changes after ampligo treatment, the arrangement of germ cells was in disorder, the interspaces between seminiferous tubules enlarged and the interstitial Leydig cells were smaller than their control. The number of cell layers of the seminiferous tubules was significantly reduced, the damage involving both germinal and interstitial (Leydig) cells. Histopathological changes were more intense in rabbits from the AP-treated group than in those from the AP+CE-treated group.

Similar results were reported in male rats exposed to other synthetic pyrethroids such as fenvalerate, permethrin and Beta-cypermethrin and lambda cyhalothrin (Elbetieha *et al.*, 2001; Mani *et al.*, 2002; LI *et al.*, 2013; khaldoun oularbi, 2014). Authors demonstrated that pyrethroid insecticide induces impairment of the structure of seminiferous tubules and spermatogenesis in the male adult rats. The said impairment may be attributed to the imbalance of circulating testosterone (Li *et al.*, 2013). Vitamins C E supplementation with AP significantly reversed the histological damages.

Figure 1: Histology of Testis: (A and B) the histoarchitecture of the testis is intact in control and CE rabbits. (C) Rabbits treated with AP show disorganization of seminiferous tubules and degeneration of the epithelium and congestion. C and D) Rabbits treated AP+ CE (Haematoxylin Eosin stain, X 400).



CONCLUSIONS

The findings of the present study clearly indicate a significant protective effect of vitamins C and E combination on testicular dysfunctions against ampligo® reprotoxicity and give explanation for the use of the antioxydant as fertility enhancer in the management of pesticide-derived male infertility.

REFERENCES

- Elbetieha A., Da'as S.I., Khamas W., et al. 2001. Evaluation of the toxic potentials of cypermethrin pesticide on some reproductive and fertility parameters in the male rats. *Arch Environ Contam Toxicol*, 41, 522-8.
- Fang L., Chen P., Xia H., Chun X. 2013. Effects of cypermethrin on male reproductive system in adult rats. *Biomed Environ Sci*; 26(3):201-8
- Guo M., Liu J.H., Ma X., Luo D.X., Gong Z.H., & Lu M.H. 2016. The plant heat stress transcription factors (HSFs): structure, regulation, and function in response to abiotic stresses. *Frontiers in plant science*, 7, 114
- Khaldoun Oularbi H. 2014. Biochemical and histopathological changes in the kidney and adrenal gland of rats following repeated exposure to lambda-cyhalothrin. *Journal of Xenobiotics*, 4(1)
- Khaldoun Oularbi H., Richeval C., Lebaili N., Zerrouki-Daoudi N., Baha M., Djennas N., & Allorge D. 2017. Ameliorative effect of vitamin C against hepatotoxicity induced by emamectin benzoate in rats. *Human & experimental toxicology*, 36(7), 709-717.
- Kili multaneous exposure to low concentrations of oestrogens has negative effects on the reproductive parameters in male Sprague-Dawley rats. *Andrologia*, 39(4), 128-135
- Li Y.F., Pan C., Hu J.X., Li J., Xu L.C. 2013. Effects of cypermethrin on male reproductive system in adult rats. *Biomed. Environ. Sci.* 26, 201-208.
- Mani U., Islam F., Prasad A.K. et al. 2002. Steroidogenic alterations in testes and sera of rats exposed to formulated Fenvalerate by inhalation. *Hum Exp Toxicol*, 21, 593-97.
- Mohamed D., Saber A., Omar A., Solima A. 2014. Effect of cadmium on the testes of adult albino rats and the ameliorating effect of zinc and vitamin E. *British Journal of Science*. 11(1):72-95.
- Ratnasooriya W.D., Ratnayake S.S.K., Jayatunga Y.N.A. 2002. Effects of pyrethroid insecticide ICON (lambda-cyhalothrin) on reproductive competence of male rats. *Asian J. Androl.* 4, 35-41.
- Shrem G., Brudner Y., Atzmon Y., Michaeli M., Ellenbogen A., & Shalom-Paz E. 2019. The influence of obesity, smoking, and serum follicular stimulating hormone in azoospermic patients on testicular sperm extraction-intra cytoplasmic sperm injection outcomes: A retrospective cohort study. *Medicine*, 98(4).
- Wang H., Wang Q., Zhao X.F., Liu P., Meng X.H., Yu T., Ji Y.L., Zhang H., Zhang C., Zhang Y., Xu D.X. 2010. Cypermethrin exposure during puberty disrupts testosterone synthesis via downregulating StAR in mouse testes. *Arch. Toxicol.* 84, 53-61.
- Yamaguchia S., Chiemi M.C., Kikuchi K., Celino F.T., Agusa T., Tanabe S., Takeshi M.T. 2009. Zinc is essential trace element for spermatogenesis. *PNAS.*; 106: 10859- 10864.
- Yousef M. I., El-Demerdash F. M., Kamil K. I., & Elswad F. A. 2006. Ameliorating effect of folic acid on chromium (VI)-induced changes in reproductive performance and seminal plasma biochemistry in male rabbits. *Reproductive Toxicology*, 21(3), 322-328
- Yousef M.I. 2010. Vitamin E modulates reproductive toxicity of pyrethroid lambda-cyhalothrin in male rabbits. *Food and Chemical Toxicology* 48; 1152-1159